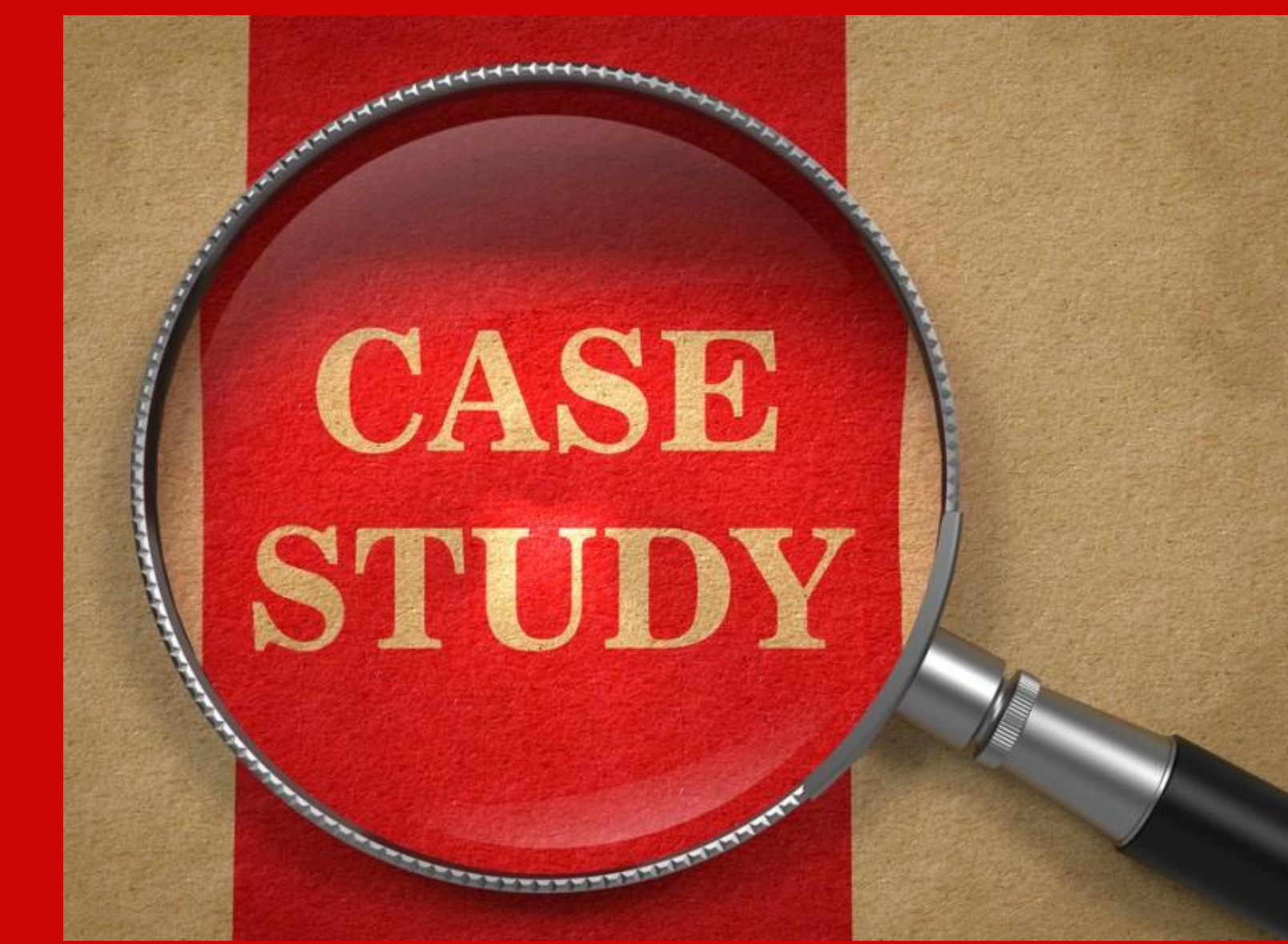

Resolution of Mixed Hearing Loss following Epithelial Debris Removal from the Tympanic Membrane

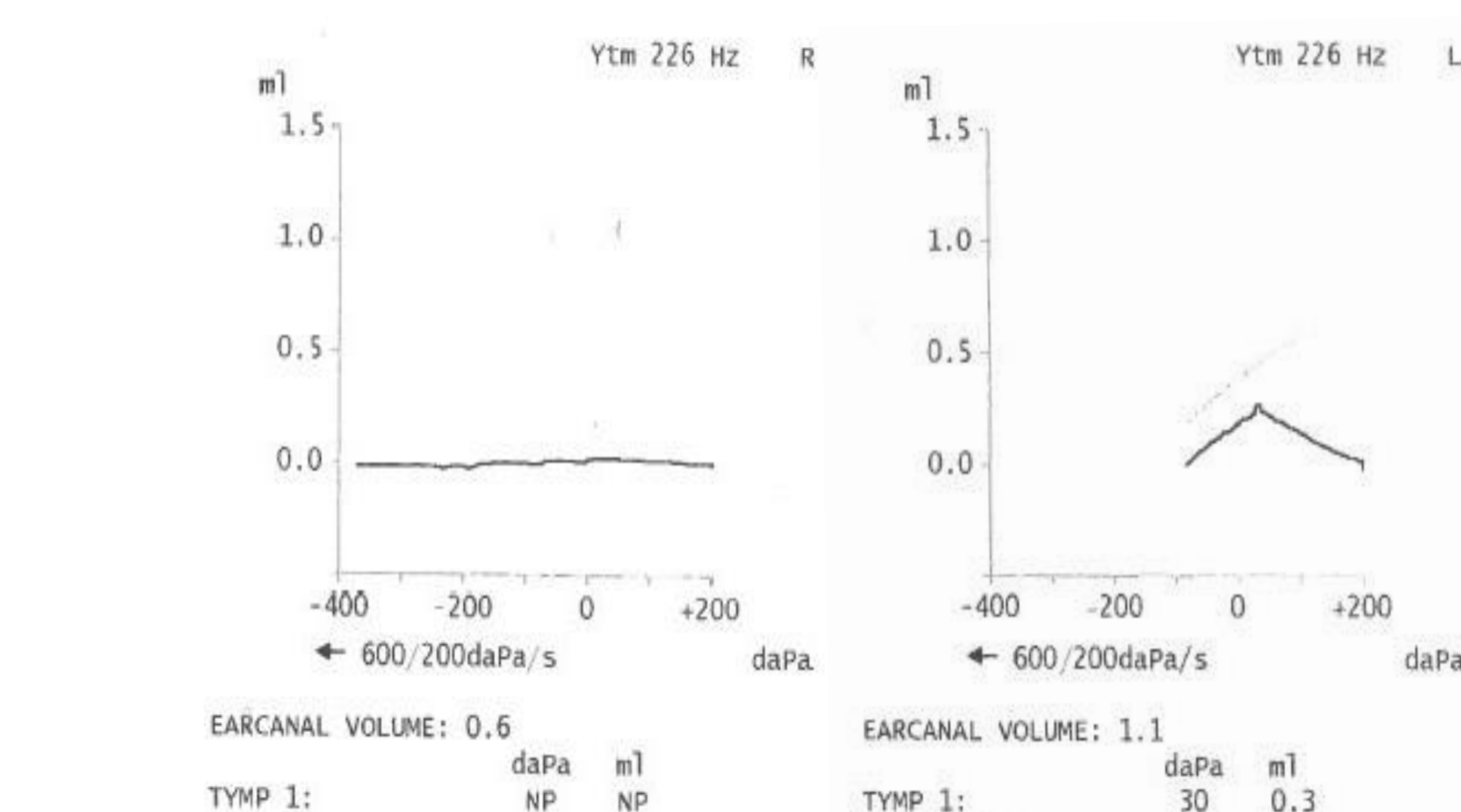
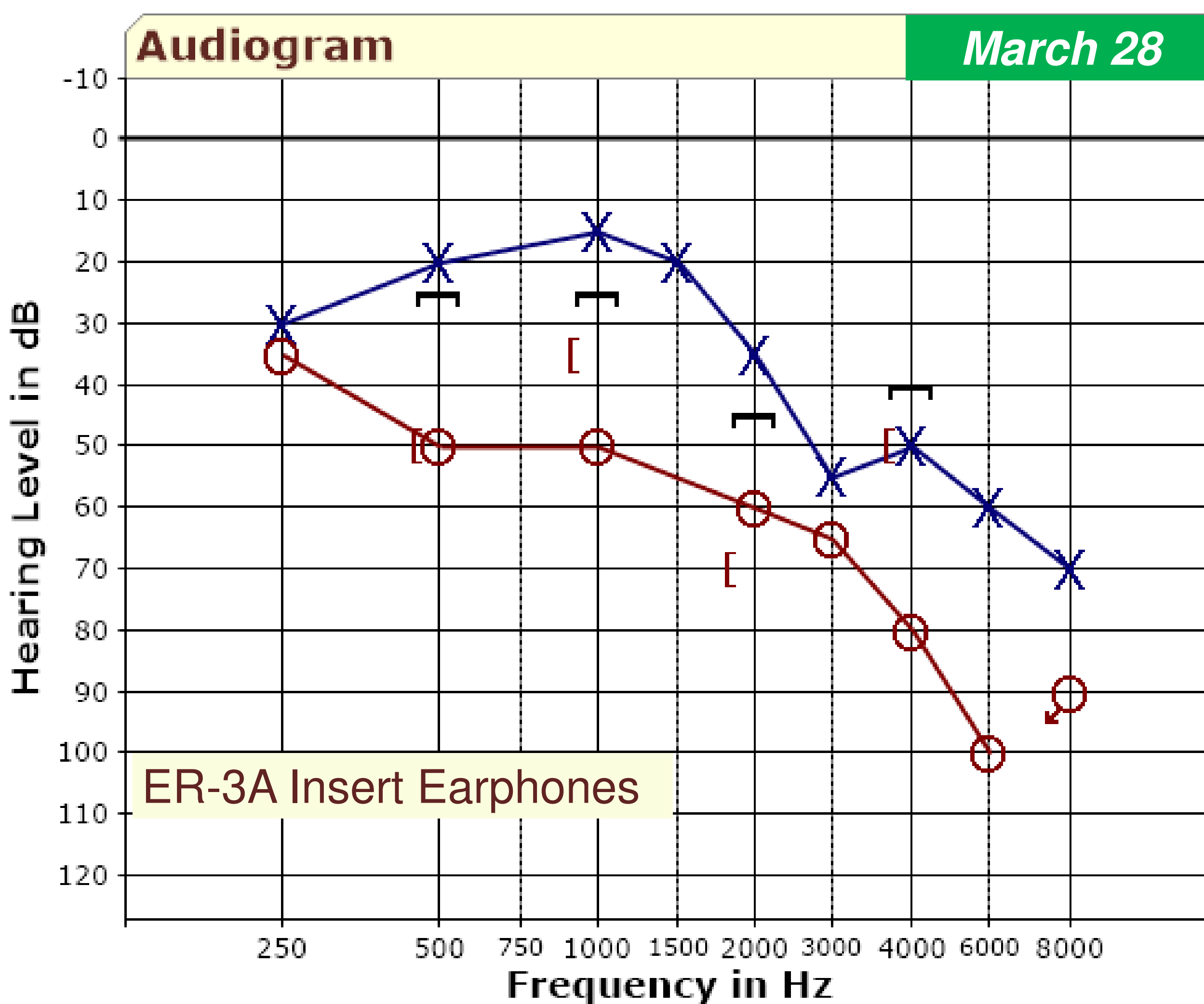
Margaret Halinski, Au.D.
Sunnyview Rehabilitation Hospital, Schenectady, NY



Case Presentation

88 year-old female presented with:

- Asymmetrical, mixed hearing loss
- Intermittent right-sided tinnitus
- No report of vertigo or ear surgery
- Medical history significant for ataxia and GERD
- Flat type B tympanogram for the right ear
- Otoscopy revealed clear ear canals with easily visualized tympanic membranes bilaterally
- Phonak Milo Plus CICs dispensed at another clinic
- Aids did not match target and were reprogrammed
- Ideal targets for the right ear could not be matched due to degree of mixed loss
- Referral was made to ENT for medical management



Case Resolution

ENT Provider #1

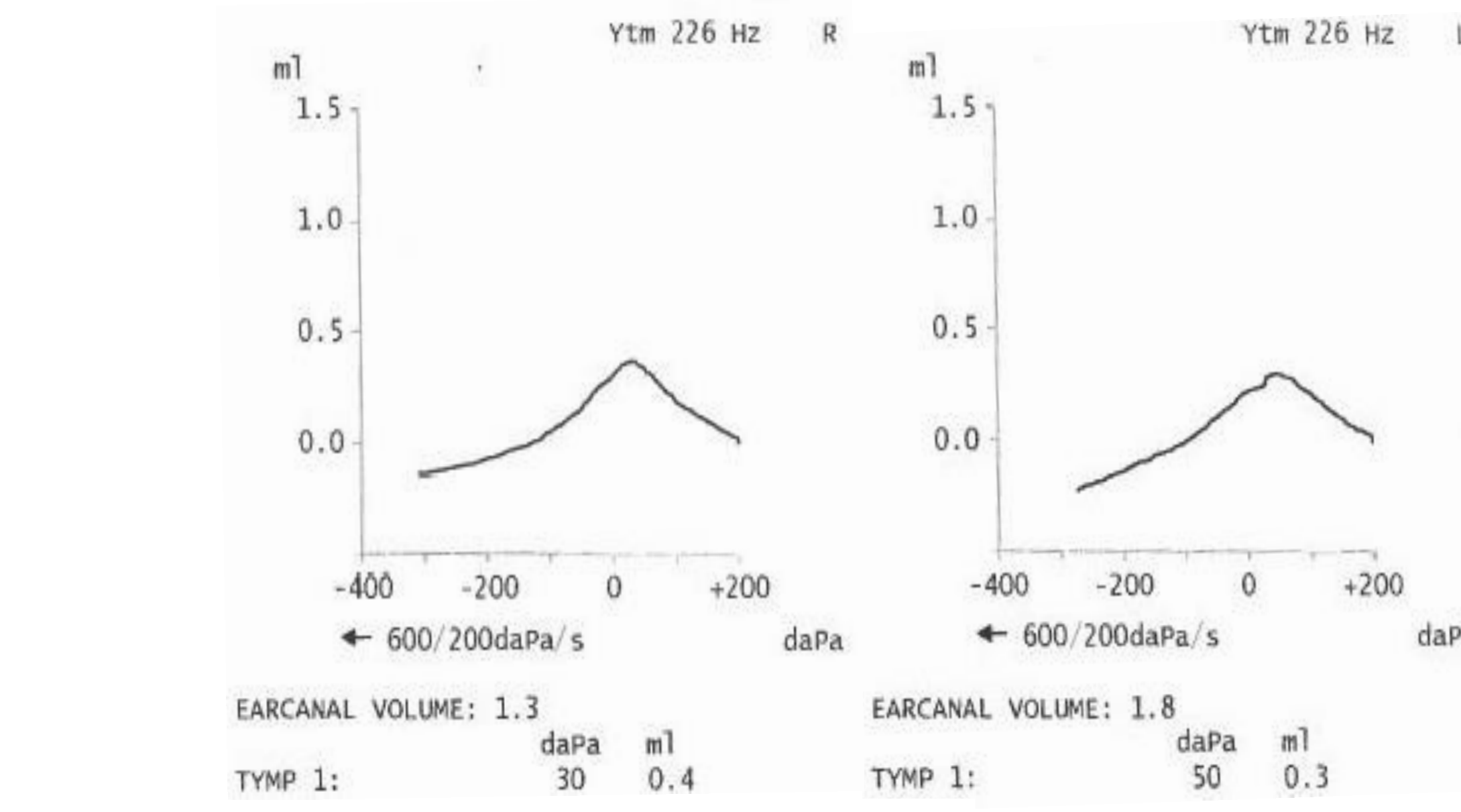
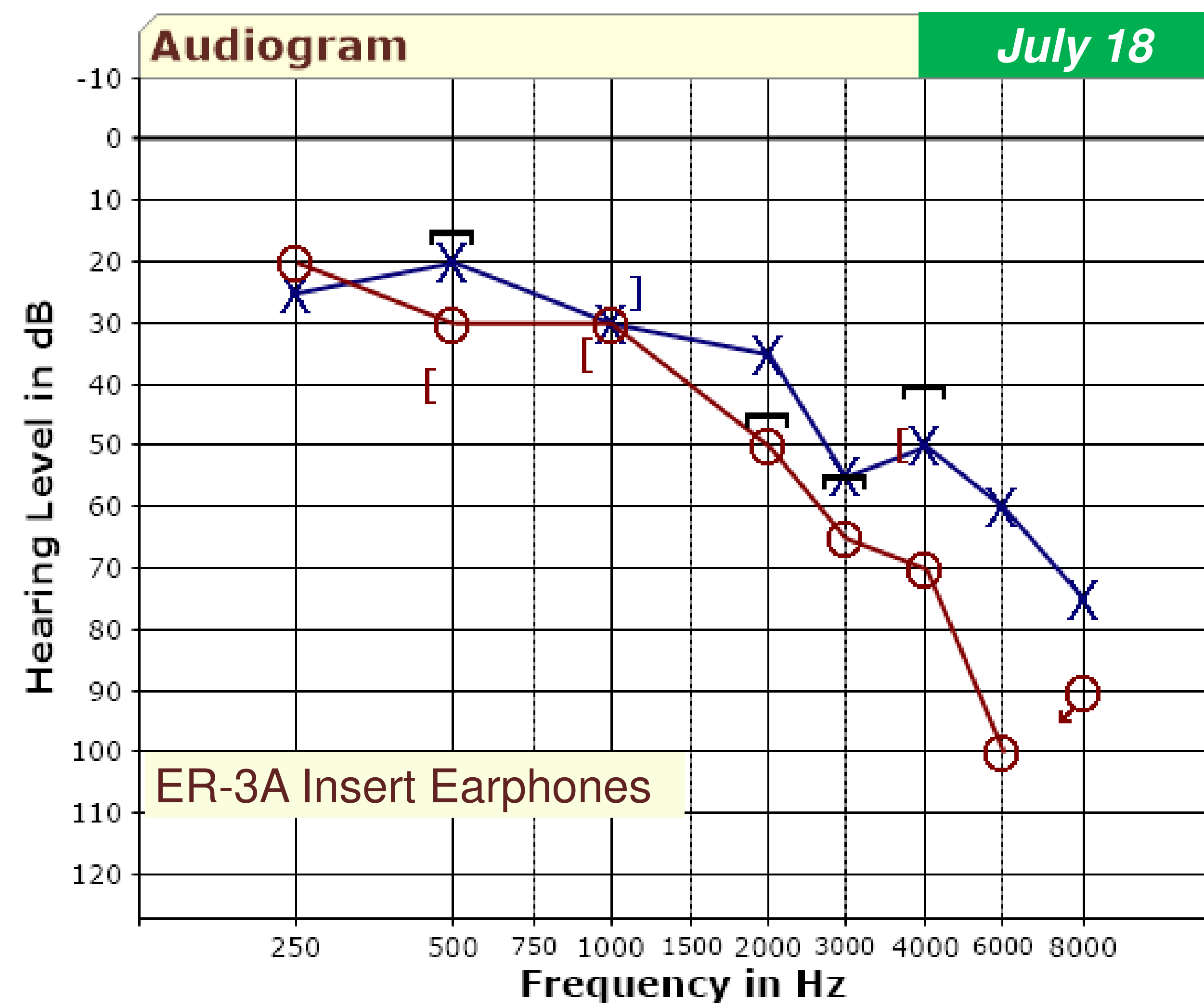
- Right myringotomy – no fluid evident
- Audiogram at ENT clinic revealed no improvement
- Report stated “no answer to flat tymp and CHL”

New hearing aid fitting

- Widex Unique 440 Fusion RIC hearing aids
- Open dome – left ear
- Custom, silicone mold – right ear
- Patient reported significant hearing improvement
- Patient expressed concerns about her ENT appointment so recommendation was made to see another ENT provider

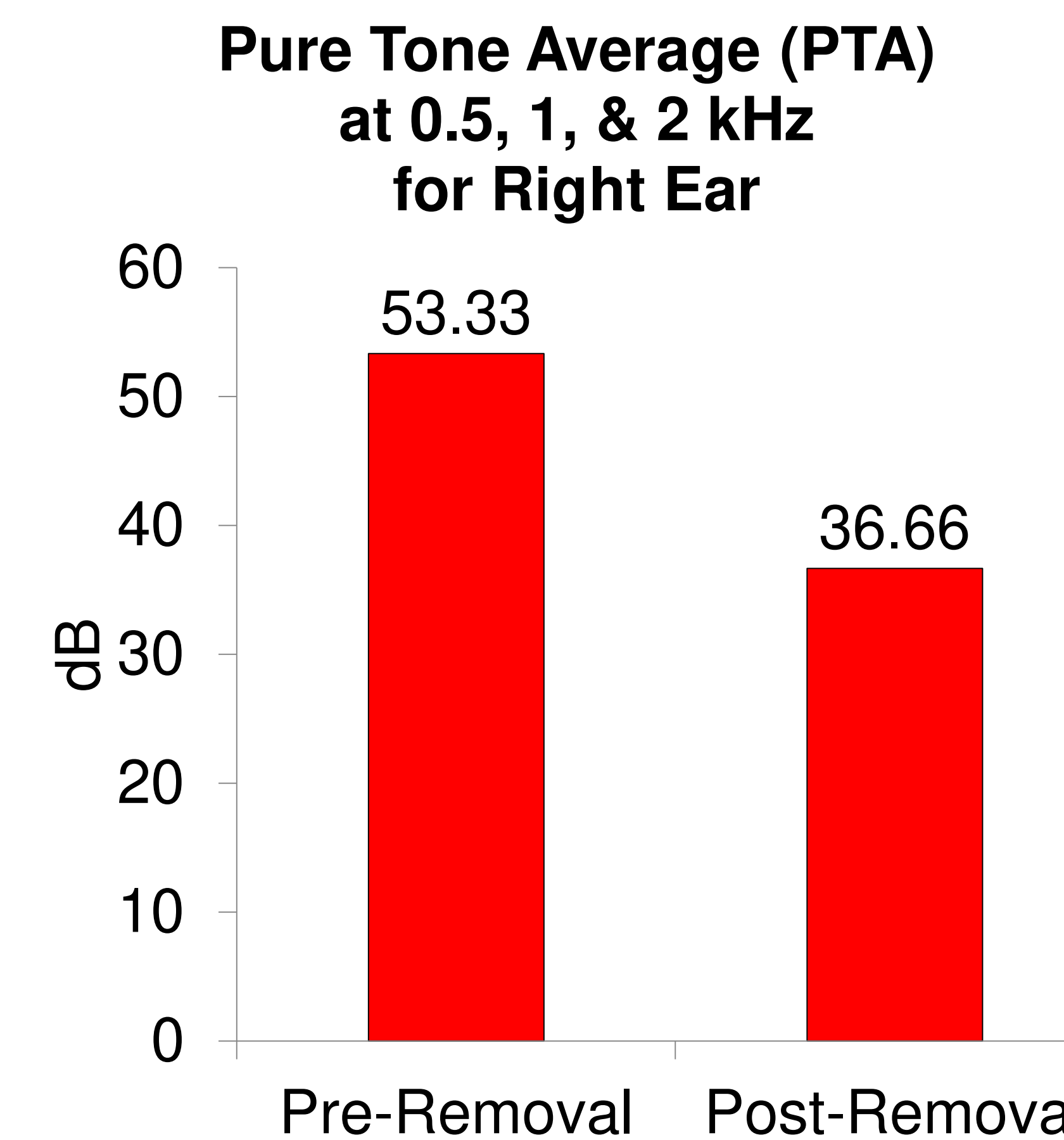
ENT Provider #2

- Right ear findings
- Negative Rinne, BC>AC; normal Weber
- Prominent anterior overhang in canal
- Debris build up medial to overhang
- Tympanic membrane (TM) had abundant crusting and epithelial debris/cast adherent to TM
- Debris was removed with alligator forceps and five suction with right angle hook
- Immediately following procedure patient noted improvement in hearing
- Positive Rinne, AC>BC



Re-evaluation

- Right ear hearing improvement at 0.25-2 and 4 kHz and right tympanometry improvement
- Symmetrical hearing from 0.25-1 kHz
- PTA improvement by 16.67 dB
- Hearing aids were reprogrammed
- Acoustic coupling for right ear was changed from custom mold to open dome



Discussion

- This case demonstrates the possibility of mixed hearing loss resolution, necessity of ENT referral, and identification of a pathology that is not readily apparent by all ENT physicians.
- Instances of epithelial debris are rare in the literature.^{1,2} Some cases of other growths on the tympanic membrane have been reported including keratosis obturans,^{3,4} fibrosis,⁵ fibroma,⁶ paraganglioma,⁷ schwannoma,⁸ cholesteatoma,⁹ hemangioma,^{10,11} and squamous cell carcinoma.¹²
- Desquamation and epithelial migration have been discussed as well in the literature,^{13,14,15} but few cases have been reported¹⁵ involving mixed hearing loss and resolution as presented in this case.

References

1. Dhillon, R. S., & East, C. A. Ear, nose and throat and head and neck surgery : an illustrated colour text (pp. 1 online resource). Retrieved from <https://www.clinicalkey.com/dura/browse/bookChapter3-s2.0-C20090437528>
2. Sagit, M., Uludag, M., & San, I. (2011). An unusual dark pigmentation on the tympanic membrane. J Laryngol Otol, 125(10), 1059-1061.
3. Park, S. Y., Jung, Y. H., & Oh, J. H. (2015). Clinical characteristics of keratosis obturans and external auditory canal cholesteatoma. Otolaryngol Head Neck Surg, 152(2), 326-330.
4. Persaud, R. A., Hajioff, D., Thevasagayam, M. S., Wareing, M. J., & Wright, A. (2004). Keratosis obturans and external ear canal cholesteatoma: how and why we should distinguish between these conditions. Clin Otolaryngol Allied Sci, 29(6), 577-581.
5. Yang, Y. S., Han, H. S., Shin, J. E., & Kim, C. H. (2016). Fibrosis Within the Tympanic Membrane. J Craniofac Surg, 27(5), e427-428.
6. Kim, C. W., Oh, S. J., Rho, Y. S., Cho, S. J., Koh, E. S., & Kang, J. M. (2009). Fibroma of the tympanic membrane. Am J Otolaryngol, 30(4), 288-290.
7. Blake, D. M., Tomovic, S., & Jyung, R. W. (2014). Tympanic paraganglioma. Ear Nose Throat J, 93(4-5), 136, 138.
8. Yang, C. H., Su, C. Y., Wei, Y. C., & Hwang, C. F. (2006). Schwannoma of the tympanic membrane. J Laryngol Otol, 120(3), 247-249.
9. Casale, M., De Franco, A., Negri, M., Piazza, F., Incammissa, A., Salvinelli, F., & Zini, C. (2012). A congenital tympanic membrane cholesteatoma (CTMC) in the adult: a case report. Eur Rev Med Pharmacol Sci, 16(5), 699-700.
10. Hiraumi, H., Miura, M., & Hirose, T. (2005). Capillary hemangioma of the tympanic membrane. Am J Otolaryngol, 26(5), 351-352.
11. Magliulo, G., Parrotto, D., Sardella, B., Della Rocca, C., & Re, M. (2007). Cavernous hemangioma of the tympanic membrane and external ear canal. Am J Otolaryngol, 28(3), 180-183.
12. de Zoysa, N., Stephens, J., Mochloulis, G. M., & Kothari, P. B. (2011). Persistent otorrhoea with an abnormal tympanic membrane secondary to squamous cell carcinoma of the tympanic membrane. J Laryngol Otol, 125(3), 318-320.
13. Makino, K., & Amatsu, M. (1986). Epithelial migration on the tympanic membrane and external canal. Arch Otorhinolaryngol, 243(1), 39-42.
14. Revadi, G., Prepageran, N., Raman, R., & Sharizal, T. A. (2011). Epithelial migration on the external ear canal wall in normal and pathologic ears. Otol Neurotol, 32(3), 504-507.
15. Stenklev, N. C., Vik, O., & Laukik, E. (2004). The aging ear: an otomicroscopic and tympanometric study. Acta Otolaryngol, 124(1), 69-76.

